

Validation of Cone Beam Computed Tomography as a Tool to Explore Root Canal Anatomy

Jérôme Michetti, DDS,* Delphine Maret, DDS, MSc,*[†] Jean-Philippe Mallet, DDS, MSc,*
and Franck Diemer, DDS, MSc, PhD*[‡]

Abstract

Introduction: Cone beam computed tomography (CBCT) can provide dentists with high-quality 3-dimensional images of dental structures because of its high spatial resolution. The reconstructions of root canal systems given by the Kodak 9000 3D were compared with histologic sections to evaluate the reliability of the reconstructions. **Methods:** Nine intact freshly extracted teeth with closed apices were scanned by using the Kodak 9000 3D (spatial resolution 76 μm and 14 bits contrast resolution). After reconstruction of the volumes, the outline of the root canals was defined by segmentation. Histologic sections were then made of each specimen at predetermined levels. After digitization (resolution, 0.5–1 μm), 2-dimensional cone beam reconstructions were compared with the outline of the canals obtained by histologic sections by using areas and Feret's diameters. The statistical analysis was performed by using the Pearson correlation coefficient. **Results:** Strong to very strong correlation was found between the data acquired by using CBCT and histology: r (area) = 0.928; r (diameter) = 0.890. **Conclusions:** The Kodak 9000 3D appears to be a very interesting, reliable, noninvasive measuring tool that can be used in all spatial planes. (*J Endod* 2010;36:1187–1190)

Key Words

Cone-beam computed tomography, root canal anatomy

From the *Faculté de Chirurgie Dentaire de Toulouse, Département d'odontologie conservatrice endodontie; [†]Centre Hospitalier Universitaire de Toulouse (CSERD de l'Hotel Dieu); and [‡]Centre Hospitalier Universitaire de Toulouse (CSERD de Rangueil), Toulouse, France.

Address requests for reprints to Dr Franck Diemer, Faculté de Chirurgie Dentaire, 3 chemin des Maraichers, 31062 Toulouse cedex09, France. E-mail address: franck.diemer@wanadoo.fr.

0099-2399/\$0 - see front matter

Copyright © 2010 American Association of Endodontists.
doi:10.1016/j.joen.2010.03.029

A good knowledge of the root canal anatomy is an indispensable prerequisite for the success of endodontic treatment (1). Particularly, the assessment of the working length (2–4) and the initial apical canal diameter (5–8) are important. At present, an easy, noninvasive 3-dimensional measuring tool of the complex root canal system in the dental office does not exist (9–12).

The root canal consists of tissues with high-density contrasts. Tachibana and Matsumoto (13) were the first to suggest using tomography to study the root canal system, but as a result of the poor resolution of conventional medical computed tomography scans, they were not able to study the root canal in detail. Recently, microcomputed tomography (μCT) has appeared to be an interesting tool for endodontic research (14), mainly because the improved resolution allows a precise 3-dimensional (3-D) reconstruction of the internal and external morphology of the tooth (15). Many applications have been successfully developed to study root canals qualitatively and quantitatively *in vitro* (16–23). However, at the moment, this imaging technique is time-consuming and therefore not suitable for the dental office.

Recently, cone beam computed tomography (CBCT) has become available for dental offices because of the reduced costs and dimension (24, 25). Unlike conventional CT scans, they have a reduced acquisition time and use lower irradiation doses. Their field of view is limited, but the spatial resolution is very good in all planes (26–28). These devices give the dental surgeon high-quality 3-D diagnostic images of the maxillofacial region and from the acquired data. An advantage of the CBCT is that the images can be studied by using different representations (multiplanar reformation, 3-D surface rendering). They can be rotated in any spatial plane without superposition of the anatomic structures (29–35).

Many dental disciplines exploit the potential of CBCT for diagnosis, decisions on therapy, and surgical preparation. At present, however, there is no application dedicated to endodontics and aimed at exploring the root canal system qualitatively and quantitatively (36–39).

Unlike μCT , the potential of CBCT to explore in detail the root canal system has not been assessed.

The aim of our study was to test the potential of the Kodak 9000 3D CBCT by comparing the cone beam 2-dimensional reconstructions with root canal contours obtained by histologic sections viewed under an optical microscope.

Materials and Methods

Specimen Preparation

Nine different intact freshly extracted teeth (1 maxillary incisor, 1 maxillary canine, 3 maxillary premolars, 1 mandibular premolar, 1 maxillary molar, and 2 mandibular molars) with closed apices were selected. The roots of each specimen were embedded in a photoelasticity clear plastic cuvette (Kartell spa, Noviglio, Italy) with Synolite resin (Gaches Chimie Spécialités, Toulouse, France) up to the cemento-enamel junction. By using a specimen holder suited to the shape of the prefabricated container, each specimen was fixed in a precise, reproducible way onto the moving arm of a small cutoff machine (diamond disk 12.7: 100 \times 0.3 mm, Asahi Diamond; Industrial Europe S.A.S., Chartres, France). This device ensured an identical specimen position at each step of the protocol and that all sections were cut in the same plane. Before CBCT acquisition, the first section was cut perpendicular to the axis of the root at 10 mm from the

apex or apices. This is the coronal section, which was used as a reference plane for the histologic or CBCT reconstructed sections.

CBCT Acquisition

Once the coronal section had been made, CBCT acquisition of each specimen was done with the Kodak 9000 3D (Kodak Carestream Health, Trophy, France). Each sample was put in the center of the cone beam (field of view, 50×37 mm), and after a single rotation, a volume with a spatial resolution of $76 \mu\text{m}$ (isotropic voxel) and a contrast resolution of 14 bits was reconstructed.

The settings on the 9000 3D were 60 kV and 6.3 mA.

Cutting of the Sections and Section Digitizing

After CBCT acquisition, parallel sections were cut every 0.8 mm by using the small cutoff machine and the specific specimen holder from the coronal section until the apex. The slices were 0.5-mm-thick (about 10 slices per sample). These slices were placed in an ultrasound bath containing 8% ethylenediaminetetraacetic acid solution for 2 minutes. The coronal and apical sides were measured after digitization under the optical microscope (BX51M; Olympus, Tokyo, Japan) by using a camera (U-CMAD3/DP20; Olympus). Magnifications of $\times 5$ or $\times 10$ were chosen according to the canal size, so that the whole contour was visible on a single image with the best resolution (0.5 or $1 \mu\text{m}$). The use of low-angle single-directional light for the observation enhanced the definition of the root canal contour.

Two values were computed by using the Image J image processing and analysis software (1.37v, Wayne Rasband; National Institutes of Health, Bethesda, MD): cross-sectional area of the root canal lumen and Feret's diameter, which defines the longest distance between 2 parallel straight lines that are tangents to the shape.

Cone Beam Reconstructions and Analysis

With the data acquired with the 9000 3D, an automatic segmentation procedure was used to reconstruct in 3-D the root canal system (Fig. 1). This procedure was the same for each specimen.

Two-dimensional reconstructions parallel to the reference coronal section were then made at the various levels used for the histologic sections of the canal. The contours of the root canal obtained from the cone beam reconstruction and the corresponding histologic

sections were compared together with the canal area and Feret's diameter.

Statistical Analysis

The statistical analysis was performed by using the Excel (Microsoft Corp, Redmond, WA) 2003 software package. The data were analyzed by using descriptive statistics including means and standard deviations. The correlation between the cone beam acquisitions and the digitized images was evaluated by using the Pearson linear correlation coefficient.

Results

From the 9 specimens (14 canals), 233 sections were compared. We excluded histologic sections when the outline of the canal was too large to fit into the field of view of the optical microscope or when the canal was incomplete (foramen). Certain apical sections from cone beam acquisitions could not be reconstructed because of the proximity of the outer surfaces of the roots.

Comparison of the measurements showed the cone beam data to be slightly smaller than the equivalent digitized data by 2.85% for the area and 2.81% for the Feret diameter.

On average, a strong to very strong correlation was found between the values obtained by CBCT and those from the histologic sections (Fig. 2): r (area) = 0.928 (standard deviation [SD], 0.163) and r (Feret's diameter) = 0.890 (SD, 0.172).

Discussion

The high spatial resolution of the Kodak 9000 3D ($76 \mu\text{m}$) offers the possibility of exploring the complete root canal anatomy in 3-D in a detailed, noninvasive way for a single or multiple root canal anatomy (Fig. 3).

The reference coronal section was composed of dentin and was thus perfectly identifiable in the reconstructed volume. With the cone beam, sections can be obtained in any spatial orientation, so the 2-D reconstructions were chosen to be parallel to the reference coronal section.

The volume tomography device we used for this study provided canal images after an acquisition time of 30 seconds, a reconstruction after 1 minute 30 seconds, and a segmentation after 40 seconds. This is significantly faster than the μCT analysis of oval canals done by Grande

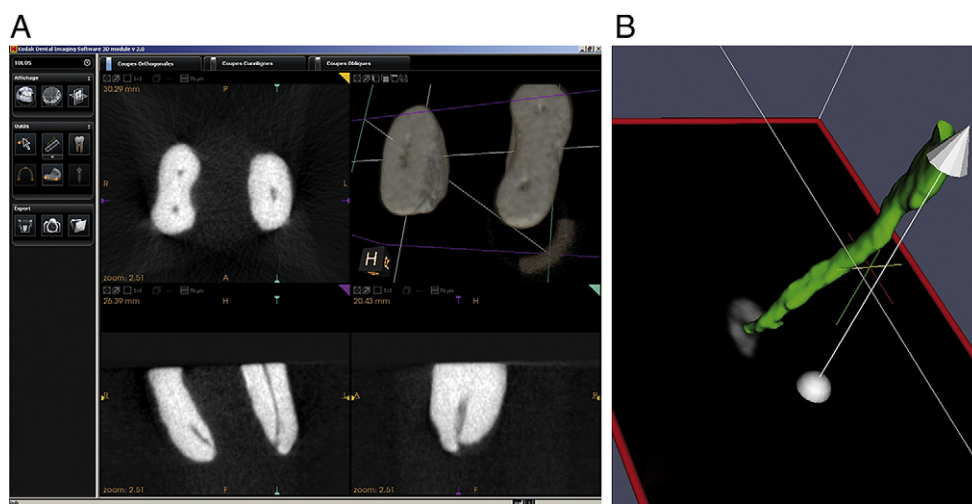


Figure 1. KDIS software interface, exploration of a mandibular molar acquisition (A); 3-D reconstruction of a maxillary second premolar canal (B). (This figure is available in color online at www.aae.org/joe/.)

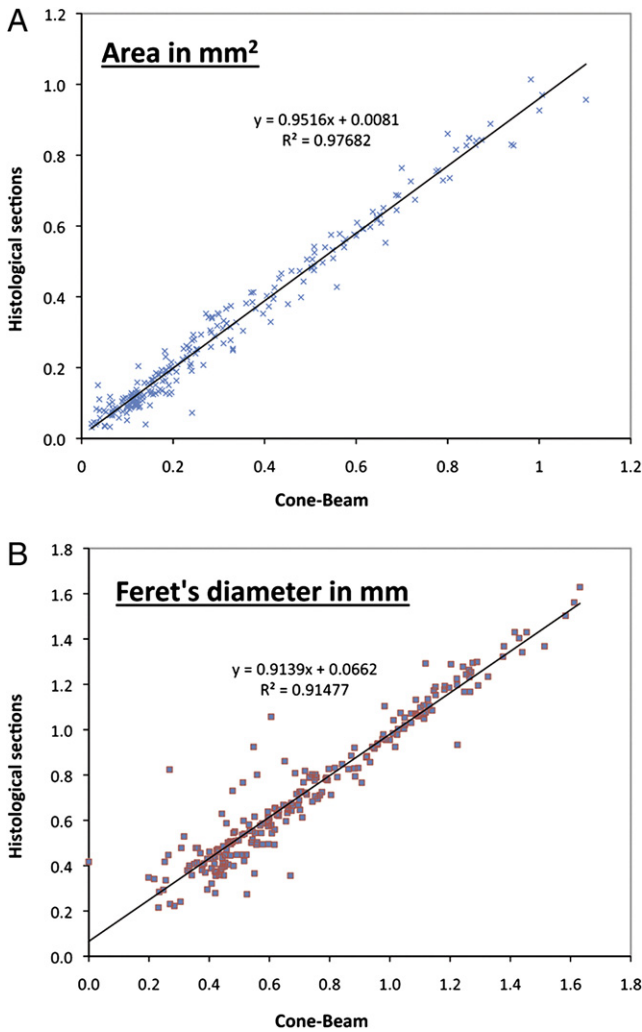


Figure 2. Scatter plot with regression line of surface area (*a*) and of Feret's diameter (*b*) of root canal sections (*n* = 233) with respect to histologic sections and CBCT. (This figure is available in color online at www.aae.org/joe/.)

et al (40). They obtained exploitable data after 2 hours of acquisition and 2 hours of reconstruction per sample, which make it clinically impractical. However, the μ CT used had a spatial resolution of 38 μ m.

Two measurements were chosen to compare contours of the root canal, the area and Feret's diameter. The latter represents the largest diameter of the outline, which is of clinical interest in endodontics. Dentists might gauge the apical canal diameter. In their research, after μ CT acquisition, Peters et al (16) recorded the mean diameter of the largest sphere that could be electronically inserted into reconstructed root canals. This measurement is called "thickness," and it was related to file tip size, which a clinician would select to gauge the apical region.

The underestimation of the canal contour by cone beam reconstructions could be due to the fact that Kodak's segmentation tool tends to smooth the canal. Actually, measurements did not consist in counting canal pixels because, after acquisition, root canal sections were just composed of a few pixels of different gray's values. The algorithm of segmentation improves images to limit the partial volume effect but not enough to reconstruct surface irregularities.

The Kodak 9000 3D used in this research had an isotropic resolution of 76 μ m. The digitized images of the microscope observations had a pixel size of less than 0.5 μ m or less than 1 μ m, depending on the magnification ($\times 5$ or $\times 10$). On average, the correlation between the 9000 3D and the histologic sections appeared higher for single-rooted specimens (*r* area = 0.985; *r* diameter = 0.975) than for multiple rooted ones (*r* area = 0.852; *r* diameter = 0.776). This difference shows that the reconstruction is more difficult, and the segmentation performance is lower for specimens with complex anatomy.

A canal contour comparison procedure similar to our protocol has already been used to assess the information provided by another computed tomography system. In 1999, Rhodes et al (23) demonstrated that μ CT was a precise, noninvasive technique for endodontic research that allowed the canal system to be explored both qualitatively and quantitatively. In that study, however, only one type of tooth (10 lower first molars) was used and only 3–4 histologic sections for each tooth. The acquisition was performed, and the histologic sections were taken after instrumentation of the canals. The μ CT device used had a spatial resolution of 81 μ m, and the digitized images had 25- μ m pixels. The correlation was high (*r* = 0.947). Our results seem to agree with those reported by Rhodes et al.

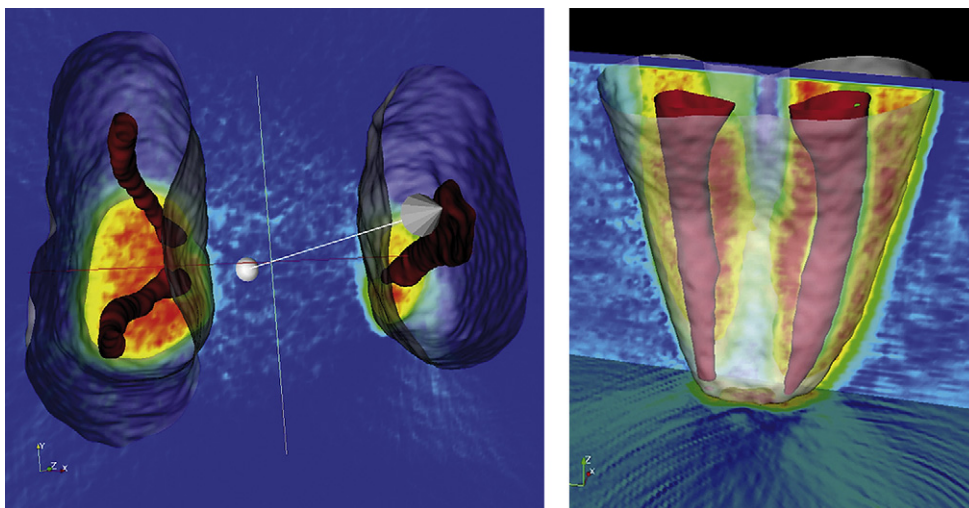


Figure 3. 3-D reconstructions of a left lower first molar (on left) and a left upper first premolar (on right). (This figure is available in color online at www.aae.org/joe/.)

Conclusion

The 9000 3D is a high-performance imaging tool because it shows the complexity of root canals in 3 dimensions. Cone beam data appear to be slightly smaller than the equivalent digitized data (less than 3%). On average, a strong to very strong correlation is shown between the cone beam reconstructions and the histologic sections: r (area) = 0.928 (SD, 0.163); r (diameter) = 0.890 (SD, 0.172).

This imaging technique, which is promising as a complementary radiologic examination, still needs further assessment, notably concerning its capacity to reconstruct canal anatomy *in vivo*.

Acknowledgments

The authors would like to especially thank Dr Lucas van der Sluis for his valuable advice and comments on the manuscript.

References

- Vertucci F. Root canal morphology and its relationship to endodontic procedures. *Endod Topics* 2005;10:3–29.
- Ricucci D. Apical limit of root canal instrumentation and obturation, part 1: literature review. *Int Endod J* 1998;31:384–93.
- Ricucci D, Langeland K. Apical limit of root canal instrumentation and obturation, part 2: a histological study. *Int Endod J* 1998;31:394–409.
- Wu MK, Wesselink P, Walton R. Apical terminus location of root canal treatment procedures. *Oral Surg Oral Med Oral Pathol Oral Radiol Endod* 2000;89:99–103.
- Kerekes K, Tronstad L. Morphometric observations on root canals of human anterior teeth. *J Endod* 1977;3:24–9.
- Kerekes K, Tronstad L. Morphometric observations on root canals of human premolars. *J Endod* 1977;3:74–8.
- Kerekes K, Tronstad L. Morphometric observations on the root canals of human molars. *J Endod* 1977;3:114–8.
- Jou YT, Karabucak B, Levin J, Liu D. Endodontic working width: current concepts and techniques. *Dent Clin North Am* 2004;48:323–35.
- Burch J, Hulén S. The relationship of the apical foramen to the anatomic apex of the tooth root. *Oral Surg Oral Med Oral Pathol Oral Radiol Endod* 1972;34:262–8.
- Dummer PM, McGinn JH, Rees DG. The position and topography of the apical canal constriction and apical foramen. *Int Endod J* 1984;17:192–8.
- Gani O, Visvisian C. Apical canal diameter in the first upper molar at various ages. *J Endod* 1999;25:689–91.
- Wu M-K, Barkis D, Roris A, Wesselink PR. Does the first file to bind correspond to the diameter of the canal in the apical region. *Int Endod J* 2002;35:264–7.
- Tachibana H, Matsumoto K. Applicability of X-ray computerized tomography in endodontics. *Endod Dent Traumatol* 1990;6:16–20.
- Nielsen RB, Alyassin AM, Peters DD, Carnes DL, Lancaster J. Microcomputed tomography: an advanced system for detailed endodontic research. *J Endod* 1995;21:561–8.
- Dowker SE, Davis GR, Elliott JC. X-ray microtomography: non-destructive three-dimensional imaging for *in vitro* endodontics studies. *Oral Surg Oral Med Oral Pathol Oral Radiol Endod* 1997;83:510–6.
- Peters OA, Laib A, Riegsegger P, Barbakow F. Three-dimensional analysis of root canal geometry by high-resolution computed tomography. *J Dent Res* 2000;79:1405–9.
- Peters OA, Laib A, Göhring TN, Barbakow F. Changes in root canal geometry after preparation assessed by high-resolution computed tomography. *J Endod* 2001;27:1–6.
- Peters OA, Schönenberger K, Laib A. Effects of four Ni-Ti preparation techniques on root canal geometry assessed by micro computed tomography. *Int Endod J* 2001;34:221–30.
- Bergmans L, Van Cleynenbreugel J, Wevers M, Lambrechts P. A methodology for quantitative evaluation of root canal instrumentation using microcomputed tomography. *Int Endod J* 2001;34:390–8.
- Peters OA, Peters CI, Schönenberger K, Barbakow F. ProTaper rotary root canal preparation: effects of canal anatomy on final shape analysed by micro CT. *Int Endod J* 2003;36:86–92.
- Lee JK, Ha BH, Choi JH, Heo SM, Perinpanayagam H. Quantitative three-dimensional analysis of root canal curvature in maxillary first molars using micro-computed tomography. *J Endod* 2006;32:941–5.
- Plotino G, Grande NM, Pecci R, Bedini R, Pameijer CH, Somma F. Three-dimensional imaging using microcomputed tomography for studying tooth macromorphology. *J Am Dent Assoc* 2006;137:1555–61.
- Rhodes JS, Pitt Ford TR, Lynch JA, Liepins PJ, Curtis RV. Micro-computed tomography: a new tool for experimental endodontology. *Int Endod J* 1999;32:165–70.
- Patel S, Dawood A, Whaites E, Pitt Ford T. New dimensions in endodontic imaging: part 1—conventional and alternative radiographic systems. *Int Endod J* 2009;42:447–62.
- Patel S. New dimensions in endodontic imaging: part 2—cone beam computed tomography. *Int Endod J* 2009;42:463–75.
- Hashimoto K, Arai Y, Iwai K, Kawashima S, Terakado M. A comparison of a new limited cone beam computed tomography machine for dental use with a multidetector row helical CT machine. *Oral Surg Oral Med Oral Pathol Oral Radiol Endod* 2003;95:371–7.
- Winter A, Pollack A, Frommer H, Koenig L. Cone beam volumetric tomography vs. medical CT scanners. *N Y State Dent J* 2005;71:28–33.
- Nair MK, Nair UP. Digital and advanced imaging in endodontics: a review. *J Endod* 2007;33:1–6.
- Mozzo P, Procacci C, Tacconi A, Tinazzi Martini P, Bergamo Andreis I. A new volumetric CT machine for dental imaging based on the cone-beam technique: preliminary results. *Eur Radiol* 1998;8:1558–64.
- Arai Y, Tammsalo E, Hashimoto K, Shinoda K. Development of a compact computed tomographic apparatus for dental use. *Dentomaxillofac Radiol* 1999;28:245–8.
- Araki K, Maki K, Seki K, Sakamaki K, Harata Y, Sakaino R. Characteristics of a newly developed dentomaxillofacial X-ray cone beam CT scanner (CB MercuRay®): system configuration and physical properties. *Dentomaxillofac Radiol* 2004;33:51–9.
- Liedke GS, de Silveira HE, de Silveira HL, Dutra V, de Figueiredo JA. Influence of voxel size in the diagnostic ability of cone beam tomography to evaluate simulated external root resorption. *J Endod* 2009;35:233–5.
- Baratto Filho F, Zaitter S, Haragushiku GA, de Campos EA, Abuabara A, Correr GM. Analysis of the internal anatomy of maxillary first molars by using different methods. *J Endod* 2009;35:337–42.
- Hassan B, Metska ME, Ozok AR, van der Stelt P, Wesselink PR. Detection of vertical root fractures in endodontically treated teeth by a cone beam computed tomography scan. *J Endod* 2009;35:719–22.
- Estrela C, Bueno MR, De Alencar AH, et al. Method to evaluate inflammatory root resorption by using cone beam computed tomography. *J Endod* 2009;35:1491–7.
- Cotton T, Geisler T, Holden D, Schwartz S. Endodontic applications of cone beam volumetric tomography. *J Endod* 2007;33:1121–32.
- Tsurumachi T, Honda K. A new cone beam computerized tomography system for use in endodontic surgery. *Int Endod J* 2007;40:224–32.
- Patel S, Dawood A. The use of cone beam computed tomography in the management of external cervical resorption lesions. *Int Endod J* 2007;40:730–7.
- Patel S, Dawood A, Pitt Ford T, Whaites E. The potential applications of cone beam computed tomography in the management of endodontic problems. *Int Endod J* 2007;40:813–30.
- Grande NM, Plotino G, Pecci R, Bedini R, Pameijer CH, Somma F. Micro-computerized tomographic analysis of radicular and canal morphology of premolars with long oval canals. *Oral Surg Oral Med Oral Pathol Oral Radiol Endod* 2008;106:e70–6.